

Islamic university

Radiology techniques Department

Theoretical Pathology

Third Stage



## PATHOLOGY LEC3

# ***CELL INJURY***

***By***

**M.sc.Nadia Alshabani**

**M.sc.Ali alruazik**

**Objectives of this lecture: at the end of this lecture, you will be able to know**

- Definition of the cell injury
- What are the types of cell injury ?
- What is the *characteristic of Reversible injury* ?

❖ Cell injury results when cells are stressed so severely that they are no longer able to adapt.

❖ The injury depends on: type of stress, severity, type of cell/tissue affected. (e.g. neurons are more susceptible to ischemic injury than skeletal muscle).

### **CAUSES OF CELL INJURY:**

❖ The causes of cell injury are classified as exogenous or endogenous, it can occur due to the following factors:

✓ Excessive or prolonged normal stimuli (e.g. hormones or growth factors).

✓ Action of toxins that inhibit the vital cell functions (e.g. protein synthesis).

✓ Deficiency of oxygen and /or essential nutrients and metabolites.

❖ Oxygen Deprivation (Hypoxia).

❖ Physical Agents

❖ Chemical Agents and Drugs

❖ Infectious Agents

❖ Immunologic Reactions

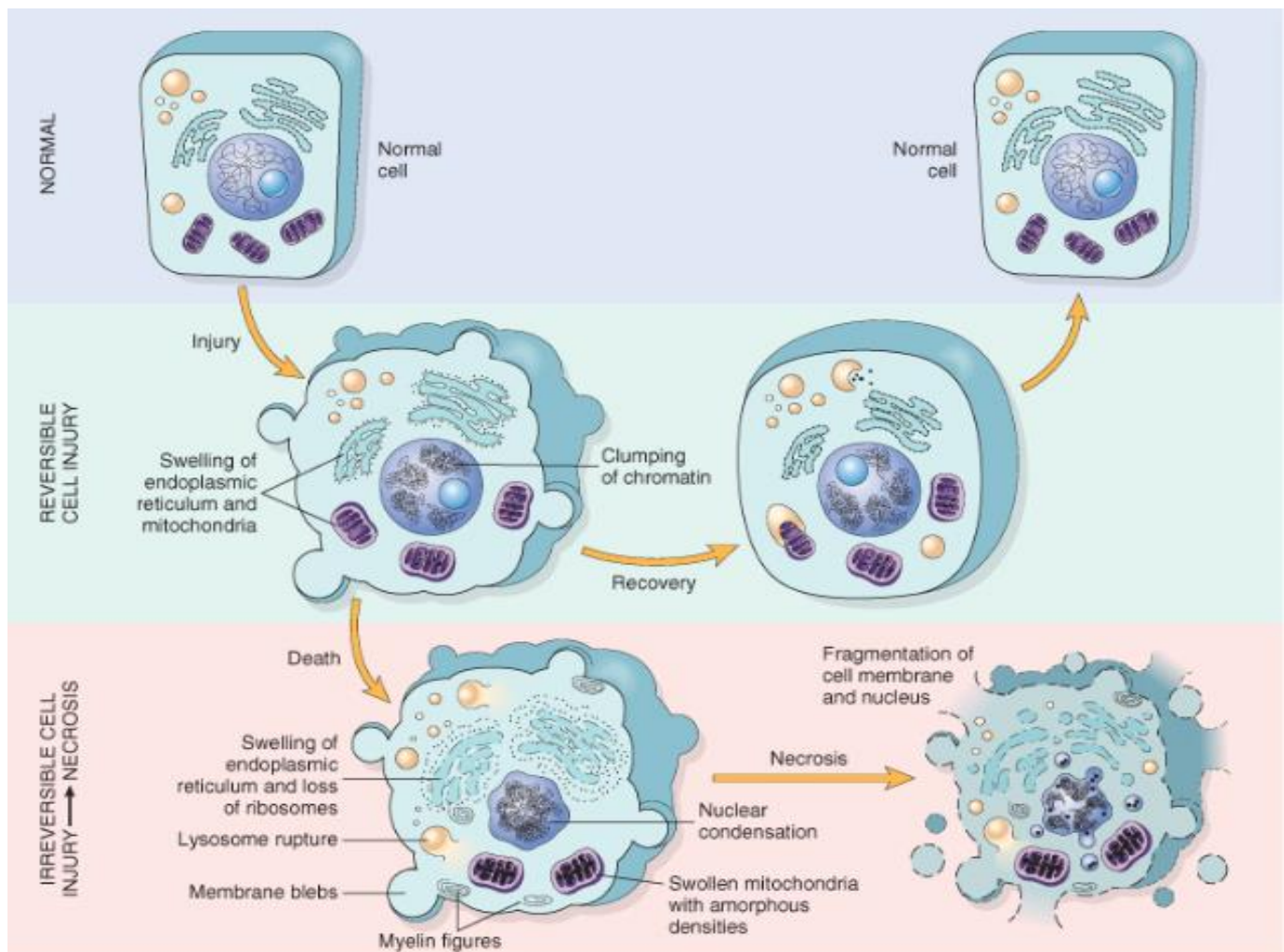
❖ **Hypoxia** is the most important cause of cell injury.

❖ Hypoxia is a relative deficiency of oxygen .

❖ Complete block in the oxygen supply is called **anoxia**.

## REVERSIBLE CELL INJURY

- ❖ In mild forms of injury, the functional and morphologic changes are reversible
- ❖ The hallmarks of reversible injury are reduced oxidative phosphorylation with resultant depletion of energy stores in the form of adenosine triphosphate (ATP), and cellular swelling caused by changes in ion concentrations and water influx.



© Elsevier 2005

### Reversible injury is characterized by:

- ✓ swelling of the cell and its organelles
- ✓ **blebbing** of the plasma membrane
- ✓ detachment of ribosomes from the ER

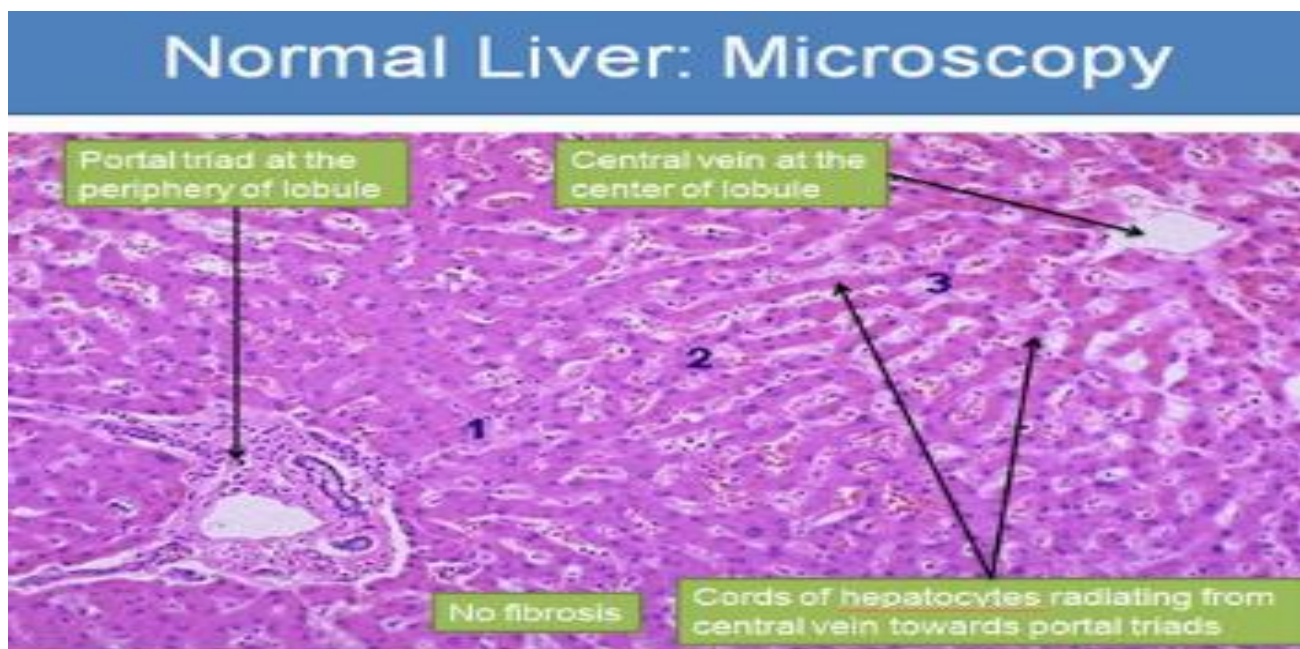
✓ clumping of nuclear chromatin.

✓ These morphologic changes are associated with decreased generation of ATP, loss of cell membrane integrity, defects in protein synthesis, cytoskeletal damage, and DNA damage.

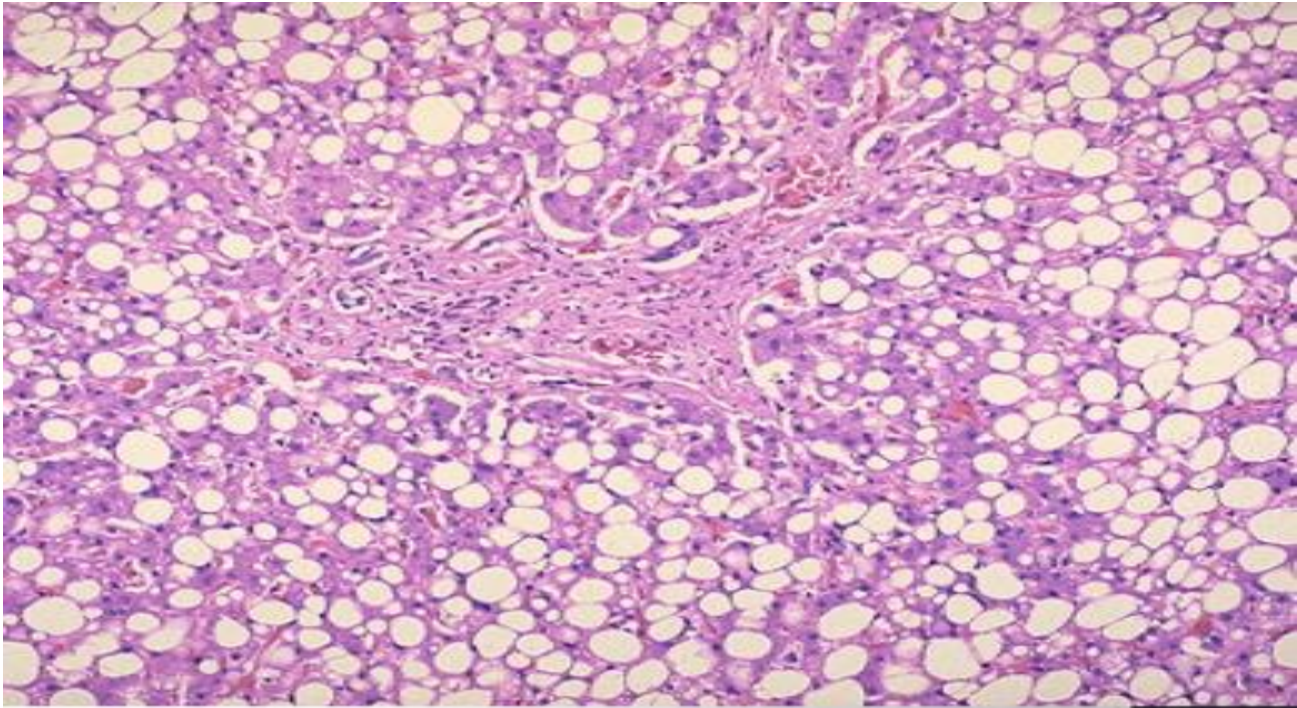
*Two features of reversible cell injury can be recognized under the light microscope:*

Cellular swelling appears whenever cells are incapable of maintaining ionic and fluid homeostasis .

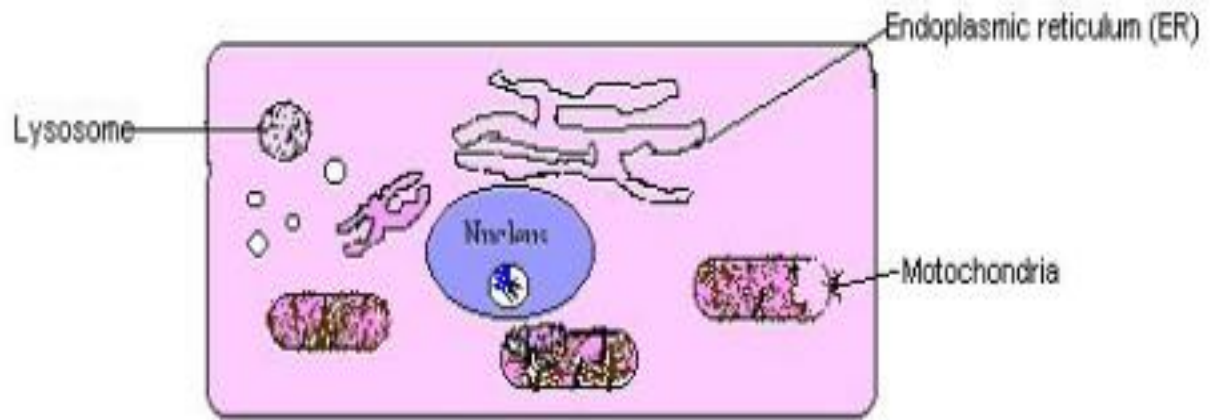
Fatty change occurs in **hypoxic injury** and various forms of toxic or metabolic injury. It is manifested by the appearance of lipid vacuoles in the cytoplasm. It is seen mainly in **cells involved in and dependent on fat metabolism**, such as hepatocytes and myocardial cells.



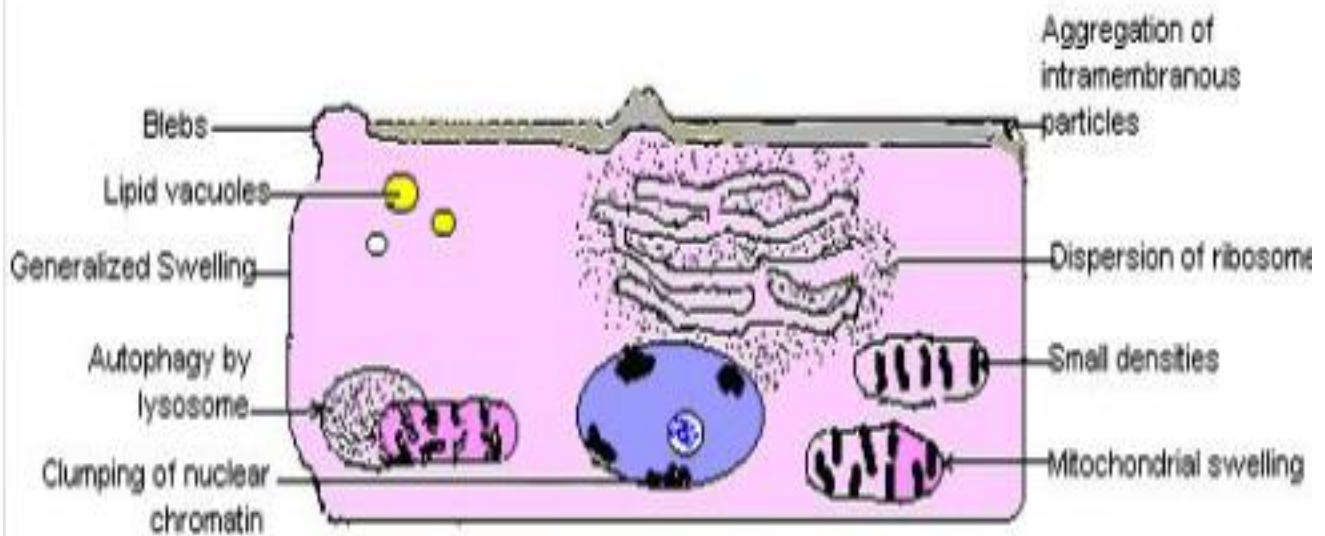
Fatty changes: Causes: alcohol abuse, protein malnutrition, obesity, diabetes, **anoxia**, toxins( carbon tetrachloride, chloroform).



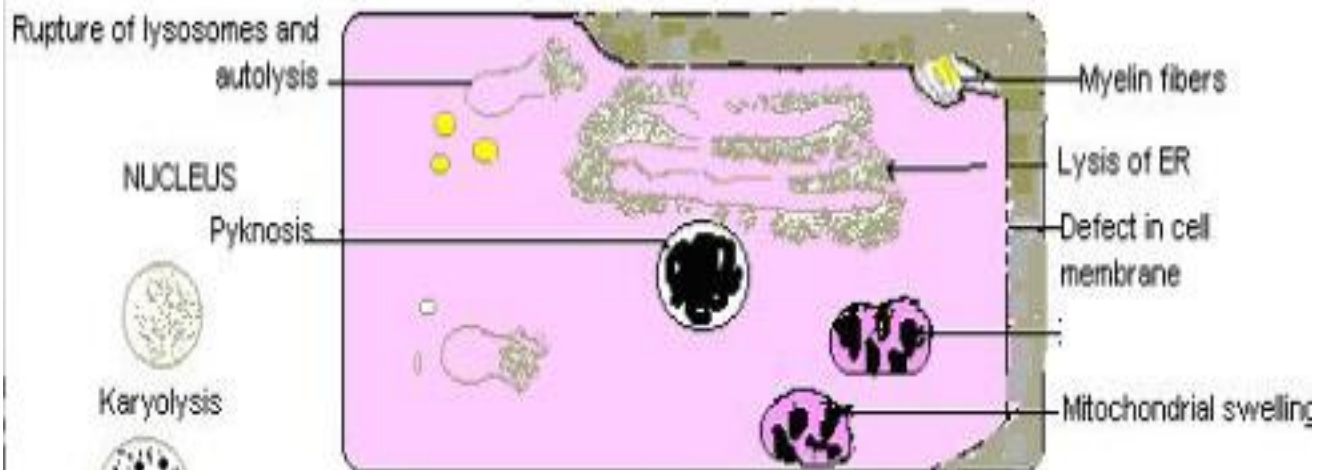
Fatty liver; many of the hepatocytes are distended with fat vacuoles pushing the nuclei to the periphery, other show multiple small vacuoles in the cytoplasm. It is a reversible cell injury.



**Normal cell**



**Reversible injury**



**Irreversible injury**